

Case Report

SEVERE OCULAR NEONATAL HERPES SIMPLEX VIRUS TYPE 2 INFECTION: A CASE REPORT

Muhammad Najmi Khairudin¹, Aida Zairani Mohd Zahidan¹, Norshamsiah Md Din¹, Ropilah Abd. Rahman*²

¹ Department of Ophthalmology, Universiti Kebangsaan Malaysia Medical Centre, Cheras, Kuala Lumpur, Malaysia.

² Kulliyah of Medicine and Health Sciences, Universiti Islam Antarabangsa Sultan Abdul Halim Mu'adzam Shah (UniSHAMS), Kuala Ketil, Kedah, Malaysia.

ARTICLE INFO

Corresponding author:
Prof. Dr. Ropilah Abd. Rahman

Email address:
ropilah_ar@yahoo.com

Received:
May 2018
Accepted for publication:
June 2018

Keywords:

Herpes simplex virus
Acute retinal necrosis
Acyclovir
tractional retinal detachment,
neonate

ABSTRACT

We reported a case of a 42 days old baby girl who was diagnosed with bilateral acute retinal necrosis with tractional retinal detachment. She was earlier diagnosed to have disseminated Herpes Simplex Virus (HSV) type 2 infection with encephalitis and treated by the paediatrics team with intravenous aciclovir. She was referred for routine eye assessment and dilated fundus examination revealed extensive peripheral retinal necrosis with some areas of resolving retinitis involving the right macula but sparing the left macula. The ocular disease progressed and tractional retinal detachment developed bilaterally needing vitreoretinal intervention. However, her systemic diseases worsened and she passed away at another tertiary hospital while waiting for the vitreoretinal surgery. This case demonstrates that a patient with such severe retinal necrosis might have normal anterior segment findings. Therefore, it is recommended that all neonates with systemic herpetic infection should be referred ophthalmological assessment early even in the absence of external eye signs as early antiviral treatment can minimise complications of acute retinal necrosis.

INTRODUCTION

Acute retinal necrosis (ARN) is an uncommon condition in immunocompetent patients. The age of presentation is usually between 20 to 60 years old (1). The most common causative organisms are Herpes Simplex Virus (HSV) type 1, HSV type 2, Varicella Zoster virus and rarely cytomegalovirus and Epstein Barr virus (1). In paediatric group, the most common organism is the HSV-2 as it is commonly seen as a fetomaternal transmission (2). This case highlights the ocular involvement in HSV type 2 infection which can be devastating despite treatment.

A 42 days old baby girl who was diagnosed of disseminated Herpes Simplex Virus (HSV) type 2 infection with encephalitis was referred for routine eye assessment. She was born via spontaneous vaginal delivery at full term with no antenatal, intrapartum or postnatal complications but her mother was tested positive for HSV-2 infection. She was started on intravenous acyclovir by the paediatrics team seven days before the referral to the ophthalmology team. Ocular examination done on the first review revealed normal anterior segment. There was no relative afferent pupillary defect. Conjunctiva in both eyes were

white and there was no eye discharge, lid swelling or eyelid skin changes. Except for bilateral mild cataract, the anterior segments findings were unremarkable in both eyes. The right and left intraocular pressure were 8 mmHg and 9 mmHg consecutively. Dilated fundus examination of both eyes revealed extensive peripheral retinal necrosis with some areas of resolving retinitis involving the right macula (Figure 1) but sparing the left macula (Figure 2). There were multiple areas of retinal haemorrhages and mild traction band seen but there was no retinal detachment noted. Both optic discs were pale.

She was diagnosed with bilateral acute retinal necrosis secondary to disseminated HSV-2 infection. The ocular management at this point was to continue with intravenous treatment of acyclovir 500mg/m² three times daily as prescribed by the paediatric team for a total duration of six weeks. Dilated fundus examinations were done by the ophthalmology team twice weekly to monitor the progress of the retinal necrosis. However, fundus review after two weeks revealed an inferior tractional retinal detachment in the right eye which then progress to involve the macula after 4 days.

(Figure 3). The left eye also started to develop tractional retinal detachment one week later. Vitreoretinal team at another tertiary hospital was consulted regarding the case and she was transferred there for further management and assessment pending surgical intervention for the retinal detachment.

There, her systemic condition deteriorated despite continuation of treatment. She developed multiple episodes of seizure secondary to the HSV encephalitis. Thus surgery to correct the retinal detachment had to be postponed. Unfortunately, baby Tan XL passed away after 2 weeks

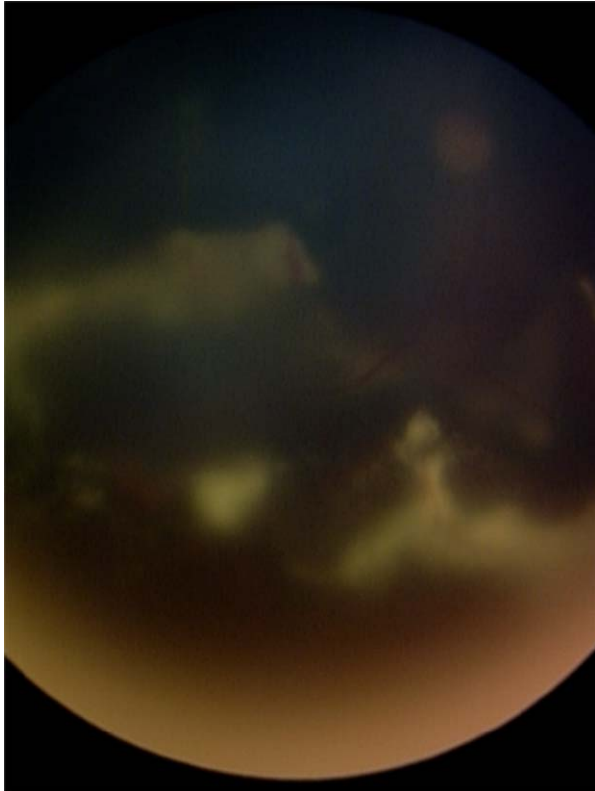


Figure 1: Retacam photograph of the right fundus showing extensive retinal necrosis involving the macula with hazy media due to vitritis

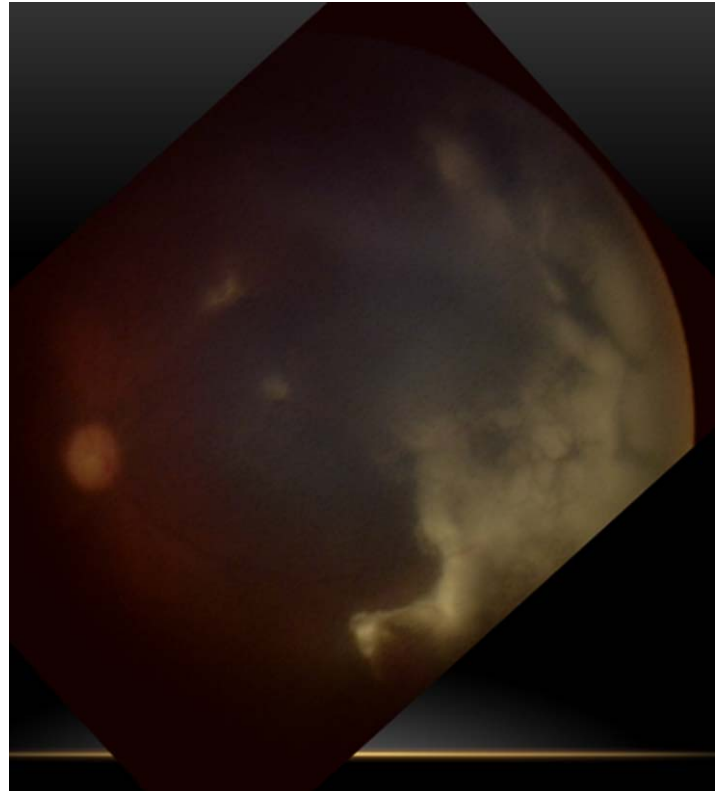


Figure 2: Retacam photograph of left fundus showing extensive necrotic retina mainly involving the temporal retina

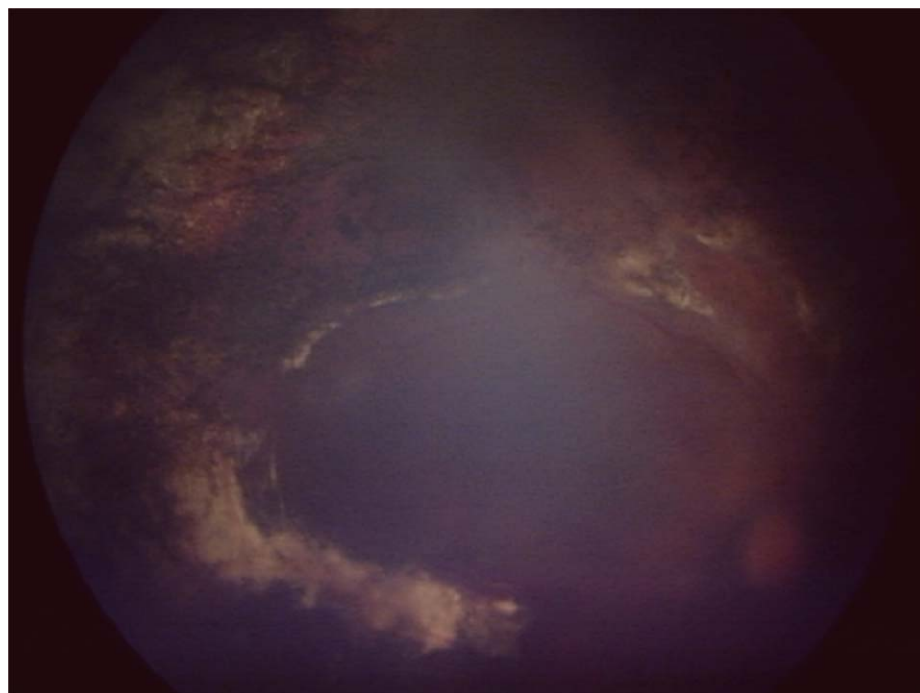


Figure 3 : Retacam photograph of the right fundus at the time of referral to vitreoretinal unit showing extensive retinal scarring with tractional retinal detachment.

of intensive therapy at the paediatric intensive care unit.

DISCUSSION

Acute retinal necrosis is a triad of peripheral necrotising retinitis, retinal arteritis and anterior uveitis or vitritis (1). The condition is relatively rare in paediatric age group. There are only several case reports published with the largest case series reported by Silva et al (2) in which they reported total number of 14 patients, aged from new-born to 21 years old who were diagnosed between 1995 until 2009 in a large tertiary centre.

There are several ways in how ARN can happen in a paediatric group. These patients might be having neonatal herpetic infection such as a disseminated infection, isolated encephalitis or mucosal herpetic infection of the skin, eye and mouth. These infections then spread hematogenously into the ocular structure causing ARN. It is also postulated that the virus can spread from the brain via axonal transmission from suprachiasmatic or periventricular nuclei towards the retina.(2) Another possible way is that ARN can also be a result of a reactivation of a latent neonatal infection which had previously taken place (3).

The most severe clinical features of ARN usually confined to the retina but anterior segment may show some periorbital skin vesicles, conjunctivitis or anterior uveitis. Retinal changes are divided into acute and late stage. Peripheral necrotising retinitis which is rapidly progressing is the most stand-out features. Other posterior segment findings in the acute stage would be vitritis, retinal arteritis and retinal edema. Late stage disease would reveal chorioretinal atrophy with scarring and tractional band. Some of the tractional band would progress into tractional retinal detachment.

Most cases of ARN can be diagnosed clinically based on dilated fundus examination due to the obvious necrotising retinitis present in all patients. It is sometime possible to identify the causative organism by obtaining sample from the ocular fluids and send it for polymerase chain reaction (PCR), culture or immunohistochemical investigations (4). In our case, the HSV-2 was detected in cerebrospinal fluid by PCR.

The mainstay of treatment in cases of ARN would be a systemic antiviral therapy. The recommended antiviral for HSV-1 and HSV-2 is intravenous acyclovir.(3) The duration of treatment depends on the clinical course. During active inflammation, it is important to administer parenteral treatment for 10 to 15 days and this might be continued with oral antiviral for another 3 months up to a year (5). Valaciclovir is reported to have better absorption compared to acyclovir thus having better ocular penetration (5).

Recent studies have suggest that there is additional benefit of combination of systemic and intravitreal

foscarnet in reducing the rate of retinal detachment and visual loss (6). However, it is also reported that intravitreal injection itself carries some risk for complications such as endophthalmitis, retinal detachment, vitreous haemorrhage and lens trauma. In addition, the availability of the medication is limited to certain countries. Our patient was only seen most likely at the late stage of the disease with retinal detachment occurring not long after the first ophthalmological review.

The role of systemic corticosteroid is controversial. However in cases with very dense vitritis, corticosteroid might be helpful. Other potential benefit of systemic corticosteroid includes minimisation of fibrosis and tractional bands formation. Some ophthalmologist also advocates barricade retinal laser photocoagulation surrounding the traction and necrotic areas as a prophylaxis to prevent retinal detachment. In cases which progressed into retinal detachment, patient needs to undergo pars plana vitrectomy and endolaser with silicone oil as tamponade to treat the retinal detachment.

This case demonstrates that a patient with such severe retinal necrosis might have normal anterior segment findings. Therefore, it is recommended that all neonates with systemic herpetic infection should be referred to ophthalmology for eye assessment even in the absence of external eye signs because early antiviral treatment can minimise complications of ARN.

REFERENCES

1. Holland GN. Standard diagnostic criteria for acute retinal necrosis syndrome. *Am J Ophthalmol* 1994;117:663-667
2. Silva RA, Berrocal AM, Moshfeghi DM et al. Herpes simplex virus type 2 mediated acute retinal necrosis in paediatric population: Case series and review. *Graefes Arch Clin Exp Ophthalmol* 2013;251:559-566
3. Corey L, Wald A. Maternal and neonatal herpes simplex virus infections. *N Engl J Med* 2009;361:1376-85
4. Pepose JS, Keadle TL, Morrison LA. Ocular herpes simplex: Changing epidemiology, emerging disease patterns and potential of vaccine prevention and therapy. *Am J Ophthalmol* 2006;141:547-57
5. Grose C. Acute retinal necrosis caused by herpes simplex virus type 2 in children: Reactivation of an undiagnosed latent neonatal herpes infection. *Semin Paediatr Neurol* 2012;19:115-118.
6. Flaxel CJ, Yeh S, Lauer AK. Combination systemic and intravitreal antiviral therapy in the management of acute retinal necrosis (An American Ophthalmological Soc Thesis). *Trans Am Ophthalmol Soc* 2013;111:133-14.